
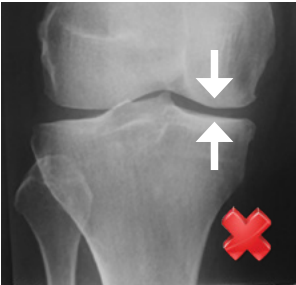
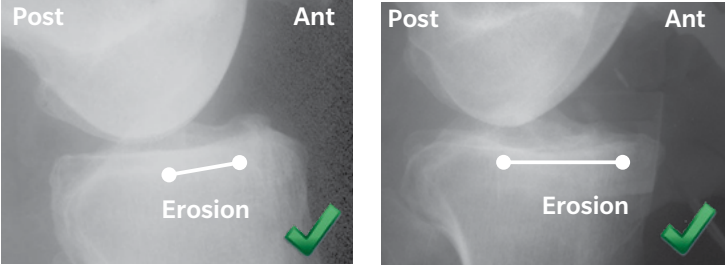
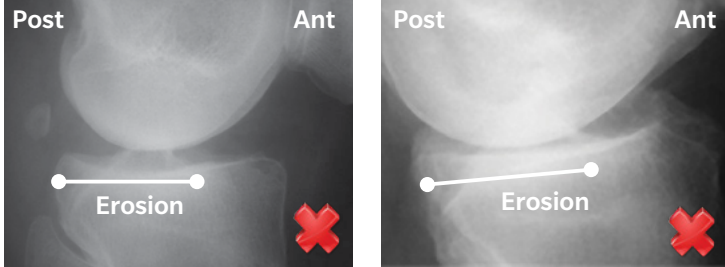
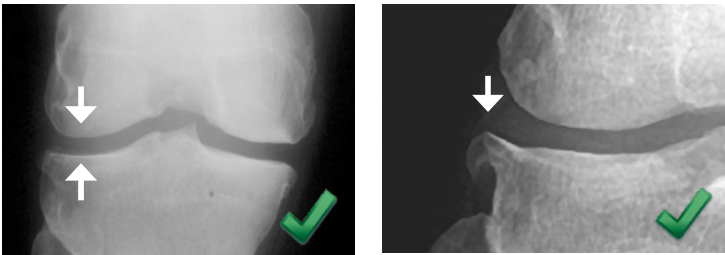
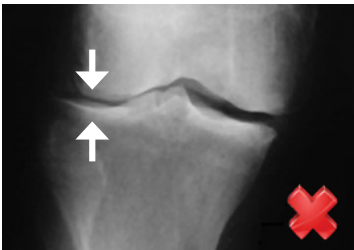
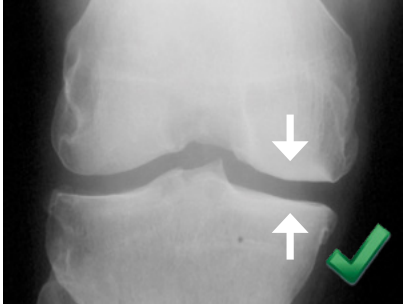
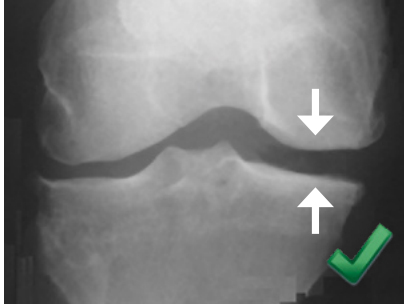
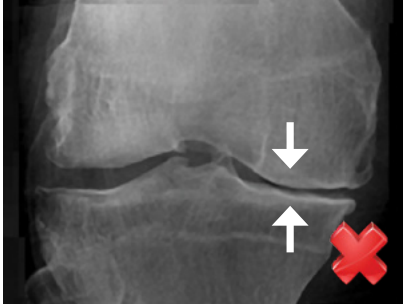


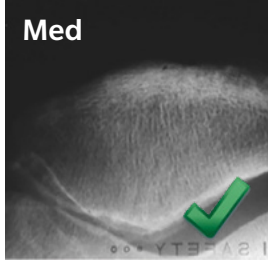
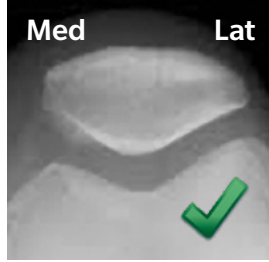
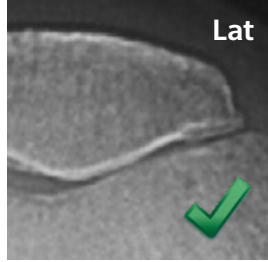
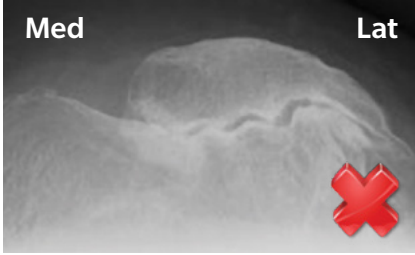
Radiographic Assessment for Medial Oxford® Partial Knee Replacement (PKR)

- See the package insert for complete indications, contraindications and patient selection criteria
- Recommended X-rays: AP weight bearing, true lateral, valgus stress & skyline. (Varus stress or Rosenberg/standing PA 20° flexion if bone-on-bone not seen on AP X-ray)
- Only proceed if **all** criteria are satisfied*

Patient Name:	
Date of Birth:	Hospital Number:
Which Knee:	
Comments:	

Criterion	Example X-rays	Conclusion
(1) Medial Bone-on-bone X-ray: <ul style="list-style-type: none"> • AP weight bearing • Varus stress (20° flexion) or Rosenberg/standing PA 20° flexion 		Bone-on-bone (or bone loss) Meets criteria
	 <p>If bone-on-bone is not seen on AP weight bearing view perform varus stress or Rosenberg/standing PA 20° flexion X-ray. If these do not show bone-on-bone consider arthroscopy. Only perform PKA if there is exposed bone on both the femur and tibia in the medial compartment.</p>	No Bone-on-bone Does not meet criteria
(2) Functionally Intact ACL X-ray: <ul style="list-style-type: none"> • True lateral (femoral condyles overlapping) 		Functional ACL (preserved posterior tibia) Meets criteria
		Absent ACL (posterior erosion/subluxation) Does not meet criteria
(3) Full Thickness Lateral Cartilage X-ray: <ul style="list-style-type: none"> • Valgus stress (20° flexion) 		Full thickness (ignore osteophytes) Meets criteria
	 <p>Repeat if inadequately stressed or X-ray not parallel to joint surface.</p>	Lateral narrowing Does not meet criteria

Criterion	Example X-rays	Conclusion
(4) Functionally Normal MCL (correctable intra-articular deformity) X-ray: <ul style="list-style-type: none"> Valgus stress (20° flexion) 		Correctable deformity (Normal medial opening) Meets criteria
		
		Repeat if inadequately stressed or X-ray not parallel to joint surface.

(5) Acceptable Patellofemoral Joint X-ray: <ul style="list-style-type: none"> Skyline 				Meets criteria Does not meet criteria
		PFJ acceptable if: <ul style="list-style-type: none"> Normal Medial facet OA, with or without bone loss Lateral facet OA, <u>without</u> bone loss PFJ not acceptable: <ul style="list-style-type: none"> Lateral facet OA, <u>with</u> bone loss, grooving & subluxation 		

Anteromedial OA is an indication for Oxford PKR. The diagnosis of anteromedial OA is based on the radiographic criteria shown above.¹ Medial avascular necrosis is also an indication. If all criteria are met, the following factors do not preclude Oxford PKR:

- Isolated medial pain is not a requirement. Pre-operative anterior knee pain has been reported to not compromise the outcome*^{2,3}
- Patient's age, weight and activity level⁴⁻⁶
- Chondrocalcinosis (cartilage calcification on X-ray), lateral marginal osteophytes or medial tibial subluxation (which should correct when the PKR is implanted if the ACL is intact)⁶⁻⁸

†The final decision on whether to perform PKA is made when the knee has been opened and directly inspected. The following factors do not preclude Oxford PKR if all other criteria are met:

- Full thickness cartilage loss on the non-weight bearing medial side of the lateral femoral^{#9}
- Full thickness cartilage loss in the patellofemoral joint* provided there is no severe damage to the lateral part of the PFJ with bone loss, grooving or subluxation.

*Patellofemoral joint damage should be limited to (or greater on) the medial facets. †Substantial walking, running, lifting, or excessive muscle loading due to weight that place extreme demands on the knee and can result in device failure or dislocation. Excessive, unusual and/or awkward movement and/or activity, trauma, excessive weight, and obesity have been implicated with premature failure of the implant by loosening, fracture, dislocation, subluxation and/or wear. †Oxford PKR is contraindicated if there is full thickness damage to the weight bearing area of the lateral compartment of the knee.

1. Hamilton TW *et al.* Radiological Decision Aid to determine suitability for medial unicompartmental knee arthroplasty: development and preliminary validation. *Bone Joint J.* 98-B(10 Supple B):3-1, 2016. 2. Berend K *et al.* Does preoperative patellofemoral joint state affect medial unicompartmental arthroplasty survival? *Orthopedics.* 34(9):494-6, 2011. 3. Liddle AD *et al.* Preoperative pain location is a poor predictor of outcome after Oxford unicompartmental knee arthroplasty at 1 and 5 years. *KSSTA* 21:2421-6, 2013. 4. Berend K *et al.* Obesity, Young Age, Patellofemoral Disease and Anterior Knee Pain: Identifying the Unicompartmental Arthroplasty Patient in the United States. *Orthopedics.* 30:19-23, 2007. 5. Kang, S. *et al.* Pre-operative Patellofemoral Degenerative Changes Do Not Affect the Outcome After Medial Oxford Unicompartmental Knee Replacement. *JBJS Br.* 93-B:476-8, 2010. 6. Pandit H. *et al.* Unnecessary Contraindications for Mobile-bearing Unicompartmental Knee Replacement. *JBJS Br.* 93-B:622-8, 2011. 7. Goodfellow JW, O'Connor J, Pandit H, Dodd C, Murray D. *Unicompartmental Arthroplasty with the Oxford Knee (2nd Edition)*, Goodfellow Publishers, Oxford, UK, 2015. 8. Kumar V *et al.* Comparison of Outcomes after UKA in Patients With and Without Chondrocalcinosis: A Matched Cohort Study. *KSSTA* 2015 online 19 March 2015. 9. Kendrick BJ *et al.* The implications of damage to the lateral femoral condyle on medial unicompartmental knee replacement. *JBJS Br* 92(3):374-9, 2010.

Disclaimer: This is a preoperative guide for X-ray assessment to determine patient suitability for Oxford medial partial knee replacement. This material is intended for health care professionals and the Zimmer Biomet sales force only. Distribution to any other recipient is prohibited. In the United States (US), the Oxford Partial Knee is intended for use in individuals with osteoarthritis or avascular necrosis limited to the medial compartment of the knee and is intended to be implanted with bone cement; it is not indicated for use in the lateral compartment or patients with ligament deficiency. Various countries outside of the US offer Oxford partial knees intended for lateral use and indicated for cementless application; these devices are not available for sale in the US. Check for local product clearances and reference product specific instructions for use. Potential risks include, but are not limited to, loosening, dislocation, fracture, wear, and infection, any of which can require additional surgery. For complete product information, including indications, contraindications, warnings, precautions, and potential adverse effects, see the package insert and www.zimmerbiomet.com. Zimmer Biomet does not practice medicine. The treating surgeon is responsible for determining the appropriate treatment, technique(s), and product(s) for each individual patient.